

Integrating Rational Emotive Behavior Therapy, Compassion-Focused Therapy with Cognitive Retraining in Traumatic Brain Injury: A Case Report

Интеграция рационально-эмоционально-поведенческой терапии и терапии, сфокусированной на сострадании, с когнитивной реабилитацией при травматическом повреждении головного мозга: клинический случай

doi: 10.17816/CP15546

Case report

Shweta Nitin Mahajan, Anuja Jain,
Shreshtha Chattopadhyay, Shamli Themse

Rashtriya Raksha University (Under Ministry of Home affairs),
Gandhinagar, Gujarat, India

Швета Нитин Махаджан, Ануджа Джайн,
Шрешта Чаттопадхьяй, Шамли Тэмс

Университет Раштрия Ракша, Гандинагар,
Гуджарат, Индия

ABSTRACT

BACKGROUND: This case report presents a novel approach to treating Traumatic Brain Injury (TBI) by integrating Rational Emotive Behavior Therapy (REBT), Compassion-Focused Therapy (CFT), and Cognitive Retraining (CR). It contributes to the literature by demonstrating the effectiveness of a comprehensive psychotherapeutic approach in managing complex TBI sequelae, particularly in the Indian context where such interventions are underrepresented.

CASE REPORT: A 34-year-old Indian female presented signs of emotional dysfunction, cognitive impairment, social maladaptation, shamefulness, and self-deprecation following a TBI sustained 10 years prior. A mental status examination and psychological assessments revealed cognitive deficits, emotional instability, and irrational beliefs, all related to her injury and recovery. The treatment plan integrated REBT, to address the irrational beliefs; CFT, to manage the sense of shame and the insistence to self-criticize; and CR, to improve cognitive functions. This approach was tailored to the patient's cognitive limitations and cultural context. Interventions included challenging irrational beliefs, self-compassion imagery, and cognitive exercises adapted to her specific deficits. Outcomes were measured using the Subjective Units of Distress (SUD) scale and clinical observations. The patient showed improvements in emotional regulation, cognitive functioning, and overall quality of life, as evidenced by reduced subjective distress (SUD down from 90 to 58) and enhanced daily functioning.

CONCLUSION: This case demonstrates that an integrated psychotherapeutic approach combining REBT, CFT, and CR can effectively address the complex psychological and cognitive challenges of TBI patients. Tailoring interventions towards patient cognitive limitations and cultural context is crucial for a successful outcome. The case highlights the importance of incorporating diverse therapeutic modalities in TBI management, promoting a more holistic approach to recovery and enhancing the quality of life of TBI survivors.

АННОТАЦИЯ

ВВЕДЕНИЕ: В данном клиническом случае представлен новый подход к лечению черепно-мозговой травмы (ЧМТ) путем интеграции рационально-эмоционально-поведенческой терапии (rational emotive behavior therapy, REBT), терапии, ориентированной на сострадание (compassion-focused therapy, CFT), и когнитивной реабилитации

(cognitive retraining, CR). Работа вносит вклад в имеющуюся литературу, демонстрируя эффективность комплексного подхода к терапии тяжелых последствий ЧМТ, особенно в Индии, где подобные вмешательства представлены недостаточно.

КЛИНИЧЕСКИЙ СЛУЧАЙ: 34-летняя женщина из Индии (пациентка VR) обратилась с жалобами на нарушения эмоциональной регуляции, когнитивные расстройства, социальные трудности, чувство стыда и самообвинение, возникшими после ЧМТ, перенесенной 10 лет назад. Психиатрическая оценка выявила наличие нарушений когнитивных функций и эмоциональной сферы, а также иррациональных убеждений относительно ее травмы и восстановления. План лечения включал сочетание REBT для коррекции иррациональных убеждений, CFT для облегчения чувства стыда и самообвинения и CR для улучшения когнитивных функций. Данный подход был адаптирован с учетом когнитивных ограничений пациентки и культурного контекста. Вмешательства включали оспаривание иррациональных убеждений, визуализацию образов для развития самосострадания и когнитивные упражнения, направленные на нарушенные у данной пациентки функции. Результаты оценивались с помощью шкалы субъективных единиц дистресса (SUD) и показателей клинических наблюдений. Пациентка продемонстрировала улучшения в эмоциональной сфере, когнитивных функциях и общем качестве жизни, о чем свидетельствовали уменьшение субъективного дистресса (оценка по SUD снизилась с 90 до 58 баллов) и улучшение повседневного функционирования.

ЗАКЛЮЧЕНИЕ: Данный клинический случай демонстрирует, что интегрированный психотерапевтический подход, состоящий из REBT, CFT и CR, может эффективно решать сложные психологические и когнитивные задачи у пациентов с ЧМТ. Адаптация вмешательств с учетом когнитивных ограничений и культурного контекста пациента является важным фактором успешного лечения. Случай подчеркивает важность включения различных терапевтических методов для целостного подхода к восстановлению и улучшению качества жизни пациентов, перенесших ЧМТ.

Keywords: *psychotherapy; traumatic brain injury; cognitive rehabilitation; case report*

Ключевые слова: *психотерапия; черепно-мозговая травма; когнитивная реабилитация; клинический случай*

INTRODUCTION

Traumatic brain injury (TBI) is a major global health concern with far-reaching consequences for individuals, families, and society worldwide [1]. Often referred to as the “silent epidemic”, TBI significantly contributes to disability and fatality rates globally [2]. Recent estimates indicate that over 69 million people suffer a TBI each year, with Southeast Asia and the Western Pacific regions bearing the heaviest burden [3].

In developing nations like India, the TBI burden is particularly concerning due to increasing industrialization, motorization, and changing social norms [4]. The impact on individuals and society is significant, yet there is a notable lack of research on TBI prevention, rehabilitation, and management in this context [4]. TBI can manifest itself in various conditions, including cognitive deficit, emotional dysfunction, difficulties to function, and sensory issues¹.

While cognitive rehabilitation has traditionally been emphasized in TBI management, psychotherapeutic approaches have received less recognition. Recent studies have explored various psychotherapeutic modalities [5, 6]. Building on this literature, we present a case study that integrates Cognitive Retraining (CR) with Compassion-Focused Therapy (CFT) and Rational Emotive Behavior Therapy (REBT) as a comprehensive psychotherapeutic management approach for TBI [7].

This case report of a middle-aged female highlights the multifaceted challenges faced by TBI survivors on a global level. By presenting this integrated approach, we aim to address the gap in the literature regarding a comprehensive psychotherapeutic management of TBI, particularly in the Indian context.

Our aim was to investigate the effectiveness of an integrated psychotherapeutic approach combining REBT,

¹ Available from: <https://msktc.org/tbi/factsheets/understanding-tbi-part-2-brain-injury-impact-individuals-functioning>

CFT, and CR in managing the complex psychological and cognitive sequelae of TBI. Specifically, we sought to do the following:

- address the gap in the existing literature regarding a comprehensive psychotherapeutic management of TBI, particularly in the Indian context [8–10];
- demonstrate the potential benefits of a holistic, patient-centered approach that factors in cognitive limitations, cultural factors, and individual needs;
- explore the synergistic effects of combining multiple evidence-based therapeutic modalities (REBT, CFT, and CR) in improving emotional regulation, cognitive functioning, and overall quality of life for TBI survivors;
- contribute to the growing body of evidence that supports the use of integrative approaches in neurorehabilitation, emphasizing the importance of psychological interventions alongside cognitive rehabilitation;
- highlight the need for tailored, flexible interventions that address both the cognitive and emotional aspects of TBI recovery simultaneously;
- provide insights into the practical application and potential efficacy of this integrated approach, laying the groundwork for future, more rigorous studies in the field of TBI rehabilitation.

CASE REPORT

Patient information

General information

Patient VR, a 34-year-old female from an urban area, complained of a decade-long history of forgetfulness, difficulty walking, and irritability, alongside a persistent low mood lasting around six years. These symptoms appeared following a TBI sustained 10 years earlier, resulting in a 27-day coma and extensive treatment. She experienced significant psychological, emotional, social, and physiological challenges, including emotional instability, depressive symptoms, and cognitive deficit. Ongoing stressors, such as interpersonal and marital issues, exacerbated her difficulties.

Medical, family, and psycho-social history

Magnetic resonance imaging (MRI) tests revealed gliotic areas in the right temporal lobe, bilateral anterior frontal lobe, vermis, and the cerebellar hemispheres, with a diffuse volume loss in the midbrain and brainstem. The patient had

a well-adjusted premorbid personality and no significant psychiatric family history. High parental expectations during childhood contributed to her internalized belief in perfectionism, causing distress across the personal, professional, and social domains.

Six months post-accident, the patient was still undergoing treatment from the hospital on an outpatient basis. The patient encountered frequent challenges during travel as her parents were elderly. To mitigate these challenges, online therapy sessions were integrated into her treatment plan to supplement in-person appointments.

The patient, a female in her late thirties, from a middle-class socioeconomic background, is educated, with an upbringing characterized by high parental expectations. The parents instilled in her the need to strive for perfection in all life endeavors. She has encountered several life challenges, including TBI, acculturative stress, job loss, and marital dissolution. These experiences have led her to internalize the belief that she must always meet high standards, fulfill others' expectations, and seek their approval.

These core beliefs in turn act as internal mandates by creating a constant drive to achieve and gain the expected validation. During challenging circumstances, these beliefs activate the internal threat system that makes her perceive such situations as fraught with potential failures or rejection. That in turn triggers in her a sense of shame, fear and self-doubt.

This behavior manifests itself in different ways:

- Drive to be flawless: she engages in behavior aimed at achieving perfection in everything she does.
- Quest for reassurance: she constantly seeks validation from others.
- Inadequate soothing system: her reliance on external validation fails to alleviate distress, reinforcing her core belief that she needs external approval to feel okay.

Her very demanding values system can further elevate the level of perceived threat in challenging situations and her beliefs in the awful likely exacerbate distress and contribute to a negative self-image.

She has unmet core needs for protection, self-worth, and compassion. The psychological consequences of these unmet needs and her core beliefs include depression, low self-esteem, social withdrawal, procrastination, difficulty with daily activities due to cognitive challenges from TBI, and impulsivity.

Her TBI has resulted in cognitive issues such as memory difficulties, executive dysfunction, slowed information processing, and the ability to think in concrete terms. The patient experiences emotional problems such as emotional dysregulation, low mood, low self-esteem, and functional problems such as social withdrawal and difficulties in daily living. She also developed various sensory issues linked to her TBI.

The activation of her threat-management capability fuels her drive, leading to behavior that seeks to achieve perfection and validation. When this behavior fails to alleviate her distress, a sense of disappointment that reinforces her core beliefs takes hold, further straining her soothing system. This cycle results in constant pressure and fear, which manifests itself in depression, low self-esteem, and social withdrawal. The cycle of distress she is trapped in is presented on Figure 1.

Clinical findings

Upon a detailed assessment and examination, the patient was presented with a constellation of symptoms indicative

of the significant neuropsychological implications of her TBI and her MRI findings. They included forgetfulness, decreased interest in pursuing any activities, low mood and slow gait, impaired immediate, recent memory, impaired social and personal judgment with ideas of hopelessness and helplessness. Psychological assessments identified deficits in cognitive domains such as speed of processing information, difficulty in sustaining attention, divided attention, verbal working memory, verbal fluency, verbal learning and memory, visual learning, logical memory, visual recognition, and retention. Additionally, other assessment results highlighted the experience of low mood, depressive tendencies, withdrawal, feelings of inferiority, and regression. Beck's depression inventory [13] was administered as a baseline assessment of subjective complaints wherein the patient presented complaints such as low mood, decreased interest in undertaking any work, and irritability. Further, interpersonal issues, which included marital adjustment problems exacerbated by the expressed emotions of her mother, resulted in emotional distress. Despite all these challenges, VR showed resilience

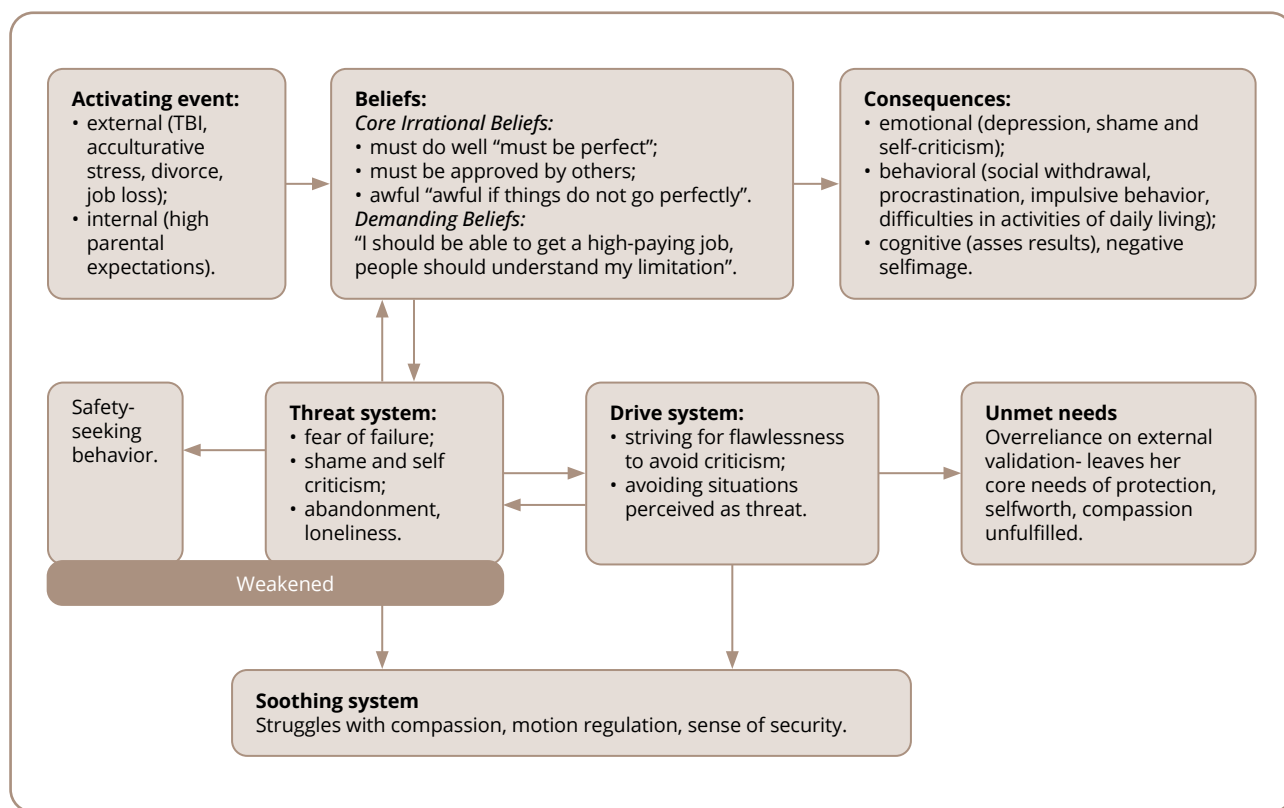


Figure 1. Psychotherapeutic formulation using REBT&CFT models, modified and compiled together by the authors [11, 12].

Note: TBI — Traumatic Brain Injury; REBT — Rational Emotive Behavior Therapy; CFT — Compassion-Focused Therapy.

Source: Mahajan et al., 2024.

and determination from the patient, who continued to actively participate in treatment.

Furthermore, her symptoms hinted at a possible organic condition or cognitive impairment, as indicated by regression and a withdrawn emotional state, which aligned with the ICD-10 diagnosis of F06.32 Organic mood (affective) disorder [14]. Thus, considering all these factors, psychotherapeutic intervention was deemed necessary.

Diagnostic assessment

Diagnostic testing

The diagnostic assessment included a comprehensive battery of tests and examinations. The MRI findings revealed gliotic areas in multiple brain regions, indicating widespread damage consistent with diffuse axonal injury. A psychological assessment, including the Depression Anxiety and Stress Scale (DASS), Human Figure Drawing Test (HFDT), National Institute of Mental Health and Neurosciences (NIMHANS) Neuropsychological Battery, and Beck Depression Inventory (BDI), was conducted. The DASS results contained a score of 28 for depression (interpreted as extremely severe), 8 for anxiety (mild), and 18 for stress (mild). The HFDT, which also serves to build rapport, presented a complex array of psychological symptoms including anxiety, depressive tendencies, withdrawal, feelings of inferiority, regression, and low energy levels. That suggested high aspirations hindered by diminished energy, fixation on past events, feelings of futility, and lack of achievement, indicating a significant emotional burden and hinting at possible organic conditions or cognitive impairment. The NIMHANS Neuropsychological Battery identified deficits in processing speed, sustained and divided attention, verbal fluency, verbal learning and memory, set shifting, verbal working memory, visual learning, and logical memory, in alignment with the diffuse nature of the brain injury.

Diagnostic challenges

The diagnostic process for VR presented several significant challenges. Foremost was the difficulty in differentiating between organic causes stemming from the TBI and psychological reactions to trauma, as symptoms could be attributed to both. This interplay made it challenging to distinguish cognitive deficits directly resulting from brain injury from those potentially exacerbated by emotional distress. VR's cognitive impairments necessitated adaptation to standard assessment procedures, potentially leading

to an underestimation of her abilities due to deficits in processing speed and attention. Cultural and contextual factors added another layer of complexity, requiring careful consideration of how cultural beliefs and societal expectations might influence symptom presentation and interpretation. Finally, the long-term nature of VR's condition, with symptoms persisting and evolving over a 10-year period since the initial injury, presented challenges in accurately assessing the progression and changes in the patient's clinical picture over time.

Diagnosis

Primary diagnosis: F06.3 Organic mood (affective) disorder (ICD-10) [15].

Other considered diagnosis: F07.2 Postconcussional syndrome (ICD-10).

Prognosis

The prognosis picture for VR is mixed, with both positive and challenging factors to consider. On the positive side, VR has shown responsiveness to the integrated psychotherapeutic interventions, evidenced by a reduction in subjective distress levels (Subjective Units of Distress, SUD [16], down from 90 to 58) and reports of enhanced ability to function. SUD is a self-assessment tool used to measure the intensity of distress or anxiety on a scale from 0 to 10, where 0 represents no distress and 10 represents the highest level of distress imaginable [16]. The patient's active involvement in treatment and the support from family members are also favorable prognostic indicators. However, several factors warrant a more guarded outlook. The chronic nature of the TBI, with symptoms persisting for over a decade, suggests that some of the deficits may have become permanent. The severity of her depression (shown as extremely severe on the DASS) and the presence of occasional self-harm ideation indicate ongoing mental health vulnerabilities. Cognitive deficits across multiple domains, as revealed by the NIMHANS Neuropsychological Battery, may limit the chances of the patient to fully recover her ability to function. Additionally, the risk of developing secondary complications or mental health issues remains a concern. Environmental stressors and the challenge of sticking to the treatment plans in the long term could also impact her recovery trajectory. Given these factors, the long-term prognosis is cautiously optimistic, but with the expectation of ongoing challenges.

Therapeutic intervention

Relevant interventions with outcomes

Patient VR is currently undergoing psychotherapeutic treatment with pharmacotherapy, including escitalopram, risperidone, and venlafaxine. To gain insight into patient strengths, weaknesses, and emotional state, various relevant psychological assessments were administered with adaptation of the process of administration to her difficulties. The assessments included DASS [17], HFDT [18], the NIMHANS Neuropsychological Battery [19], and two subtests of the Post graduate institute battery of brain dysfunction [20].

The psychotherapeutic management approach took into account the cultural and religious aspects and incorporated a combination of REBT, CFT, and CR spread across the

sessions. The sessions involved rapport establishment, psychoeducation, addressing and exploring the emotional impact and cultural beliefs, and curating techniques tailored to her cognitive limitations, as well as keeping the sessions short between 35 and 40 mins.

Types of therapeutic intervention

The following therapeutic interventions were used on the patient (Tables 1 and 2).

1. CR.
2. REBT.
3. CFT for the family:
 - training family members on active listening skills;
 - teaching assertive communication techniques (e.g., using 'I' statements, expressing needs clearly);

Table 1. The techniques and intervention procedures used during psychotherapy sessions originally by the authors

Session	Techniques	Procedure
1	Rapport building, explaining therapy process	Established a trusting and collaborative relationship. Explained the therapy process, including duration, typical flow of sessions, and ethical considerations (confidentiality, etc.).
2	Explore self-harm ideation	Explored any history of self-harming thoughts or attempts. Discussed about occasional thoughts of self-harm.
	Address the emotional impact of TBI and cultural beliefs	Explored feelings of guilt, helplessness, self-criticism, and shame related to cultural beliefs and TBI.
3	Address sexual health concerns	Assessed comfort level and specific questions about sexuality and reproduction. Provided psychoeducation about sexual intimacy, intercourse, conception, and childbirth. Debunked myths surrounding these topics using basic diagrams and analogies.
	Educated caregivers	Conducted separate sessions with caregivers to facilitate open communication and expression of emotions. Provided information about TBI, its psychological effects, and supportive strategies for recovery.
4	Promoted self-awareness and self-management	Introduced weekly schedule planning to manage activities. Practiced a short body scan relaxation technique.
5	Introduced CBT	Discussed CBT as a potential therapeutic approach after initial discussions and goal setting. Explained the concept of CBT case formulation and its potential benefits in patient treatment.
6	Adapted therapy approach to cognitive limitations	Acknowledged patient difficulty in understanding CBT due to the impact of brain injuries on ability to process information and undertake cognitive tasks. Emphasized that different people have different therapeutic needs and that finding a suitable approach is crucial. In a supportive manner and with empathy, inquired about the specific challenges she faced with CBT. Explored alternative therapeutic options that would align with patient learning style, cognitive abilities, and goals were refined.
7-9	Manage emotional distress	Implemented a multifaceted approach combining: <ul style="list-style-type: none"> • REBT to identify and challenge harmful beliefs contributing to her emotional distress; • CFT to cultivate self-compassion and manage stress using techniques like soothing rhythm breathing and calming body scans (adapted for patient cognitive limitations); • CR to improve cognitive functioning.
10-12	CFT techniques	Introduced CFT techniques like soothing rhythm breathing and calming body scans, adapted for her cognitive limitations, to help patient manage stress and cultivate self-compassion.
13-14	Conducted a neuropsychological assessment	Administered a comprehensive neuropsychological assessment to evaluate her cognitive functioning in more detail.
15-16	Reinforced previously learned concepts	Reviewed and re-addressed concepts previously discussed in therapy. Social skills exploration activity.

Note: TBI — Traumatic Brain Injury; CBT — Cognitive Behavioral Therapy; REBT — Rational Emotive Behavior Therapy; CFT — Compassion-Focused Therapy; CR — Cognitive Retraining.

Table 2. Cognitive domains with deficit, related exercises with description created and used during therapy sessions

	Exercises	Description
Processing speed	Cooking, cleaning	Engaging in household tasks that require quick decision-making and coordination.
	Sudoku, crossword puzzles	Solving puzzles that require fast thinking and response.
	Categorizing shopping list	Organizing a shopping list into categories quickly and efficiently.
Sustained attention	Jigsaw puzzles	Focusing on completing a puzzle over an extended period of time.
	Mandala coloring	Engaging in detailed and intricate coloring activities that require sustained focus.
	Bird watching	Observing birds and noting their behaviors for a prolonged period.
	Sorting lentils	Sorting different types of lentils or grains, requiring continuous attention to detail.
Divided attention	Mantra yoga	Practicing yoga while simultaneously chanting mantras, requiring focus on both physical and verbal tasks.
	Folding clothes with conversation	Engaging in a conversation while folding clothes, balancing attention between the task and the interaction.
Verbal fluency	“Name That Game”	Naming items in a category quickly (e.g., animals, fruits).
	Alphabet challenges	Generating words that start with each letter of the alphabet under time constraints.
	Word chains	Creating a chain of words where each new word starts with the last letter of the previous word.
Verbal working memory	Short stories with questions	Listening to short stories and answering questions about them to test retention and recall.
	Instruction relay	Following a series of instructions relayed verbally in sequence.
	Question chain	Answering a series of related questions where each response depends on recalling the previous question and answer.
Set shifting	Opposite word chain	Naming opposites of given words quickly (e.g., hot-cold, big-small).
	Sorting of lentils, objects, vegetables	Switching between different sorting criteria (e.g., by size, color, type) to practice cognitive flexibility.
Verbal learning & memory	Free recall	Recalling lists of words or items freely after a short delay.
	Review the day	Reviewing and recounting events of the day to enhance memory recall.
	Active listening	Engaging in conversations with active recall of details discussed.
Visual learning and logical memory	Object observation & drawing	Observing objects and then drawing them from memory to enhance visual recall.
	Spot the differences	Identifying differences between two similar pictures to practice visual discrimination and memory.
	Story sequencing	Arranging story elements or pictures in the correct sequence to improve logical memory and understanding of narrative structure.

- supporting her development of social skills (e.g., role-playing social interactions, practicing conversation starters);
- managing challenging behavior that might appear due to communication difficulties;
- setting clear and consistent expectations for communication within the family and VR.

Follow-up and outcomes

SUD were assessed at the beginning of each session using a 0–100 scale, where 0 represents no distress and 100 represents maximum distress (Figure 2). VR was asked to rate patient overall emotional distress level related

to her TBI symptoms and daily functioning ability. This provided a consistent measure of her perceived stress levels throughout the treatment process. After a gap of two sessions, SUD was taken from VR. Initially it stood at 90 at baseline. After follow up 1, which corresponded to the 4th session, it was reported to be 85, an indication of slight improvement. This continued until the next follow up of SUD. Despite the slight improvement after the second follow up, there was a minor increase to 88 in the third follow up session of SUD. Thus, the reasons for that were explored and alternate therapy approaches were also explored, ranging from the cognitive-behavioral approach to a combination of REBT and CFT. In the next 4th follow up

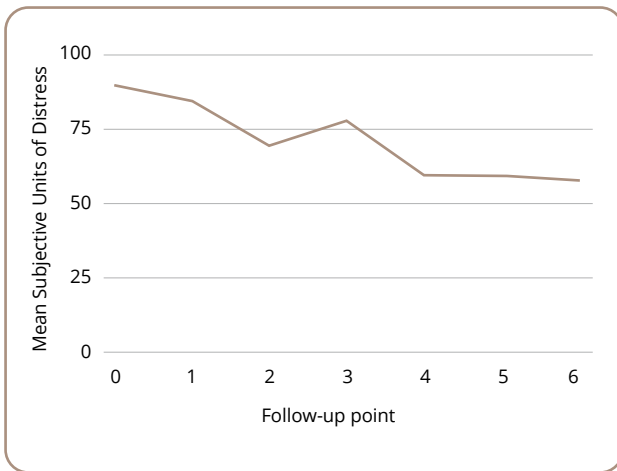


Figure 2. Mean Subjective Units of Distress according to the consequent follow-ups.

Source: Mahajan et al., 2024.

session of SUD, it had fallen to 60 and remained there until the next session, which suggests that the exercises and interventions tailored to the patient’s cognitive capacities

may have had a more substantial reduction impact on the distress levels. The sessions focused on challenging irrational beliefs, self-compassion imagery, and daily diary writing. In the last follow-up session after two therapy sessions, SUD was reported to be 58 out of the 100, which highlights the possible positive impact of the intervention and psychotherapeutic sessions on the patient.

Timeline

The patient timeline is presented in Table 3.

DISCUSSION

Clinical case summary

The present case report of TBI highlights the importance of a comprehensive psychotherapeutic approach, especially when psychotherapeutic management is not readily available, whether in a global or Indian context. Thus, this case report adds to the existing literature by addressing the existing gap through the application of integrated psychotherapeutic modules and finding them suggestively

Table 3. Patient VR chronology of disease development, key events and prognosis

Time period	Key events	Condition
Pre-accident	Completed post-graduate degree. Started working in professional roles.	Normal development, above-average student.
Year 0	The patient was in a serious accident, suffered head injury. In coma for nearly a month.	Bedridden, assisted self-care, crying, limited communication.
Year 0+6 months	Moved to spouse's family home.	Slight improvement: could eat independently, walk and talk a little. Experienced sadness, anger, suicidal thoughts. Difficulty adjusting due to cultural and economic differences.
Year 1	Returned to parental home.	
Year 2	Divorced by first spouse due to interpersonal issues and behavioral changes. Lost job.	Experienced feelings of loneliness, shame, and self-blame.
Years 2–5	Gradual physical recovery at home. Started helping with house chores and minor purchases.	Persistent low mood and worry about the future.
Year 5–8	Entered second marriage.	Experienced difficulty in establishing relationship due to educational differences. Continued feelings of low mood and increased irritability.
Year 8 (6 months prior to the assessment)	Estranged from second spouse due to interpersonal problems. On the verge of second divorce. Began psychotherapeutic treatment and pharmacotherapy.	
Current status (at time of the assessment)		Ongoing psychological concerns: <ul style="list-style-type: none"> • forgetfulness; • difficulty walking; • irritability; • guilt and shame; • low mood; • undergoing treatment.

effective based on a single case study, because the overall tendency seems to be to focus on surgical intervention and the management of psychiatric disorders and the implications of TBI but less on psychotherapeutic work.

Summary interpretation of the results

According to existing research, TBI survivors often face multifaceted challenges that can range from sensory problems to cognitive deficits and personality changes [21]. However, from the perspective of gender studies, women, especially, may encounter unique challenges due to gender roles and societal expectations, as well as physiological changes which are nonexistent in men [22]. This was the scenario in the case of patient VR, wherein the challenges faced by her were exacerbated by cultural-societal pressures and a history of high parental expectations, which led to emotional distress and internalized stress. This was the fallout that was addressed in the sessions exploring how the cultural and societal expectations had become integral to her identity and recovery process.

Additionally, in her case, establishing a trusting and collaborative therapeutic alliance was key. According to the literature, a therapeutic alliance which is collaborative in nature plays an important role in improving outcomes for individual patients with TBI².

The therapeutic results indicate the effectiveness of this combined approach. VR showed improvements in the ability to function daily, emotional management, and cognitive capacities. This is consistent with studies that argue for an integral approach to therapy after a brain injury, to accommodate the specific needs of patients [23].

This case emphasizes the importance of comprehensive neurorehabilitation programs that incorporate psychological therapies into cognitive rehabilitation. This holistic approach can help patients live meaningful lives despite their injuries. Therapists dealing with patients who have suffered a TBI should appreciate their patients' strengths, accept their new limitations, and be prepared to deal with the emotional issues that are inherent in such cases [24], which in turn highlights the need to train mental health professionals in that direction.

Practical constraints, such as a dearth of skilled experts and excessive caseloads, must be addressed in order to be able to offer adequate care to patients. Future

considerations should focus on designing, conducting, and implementing programs that train therapists to work efficiently in the area of neurorehabilitation. The available body of research underscores the importance of tailoring a variety of therapeutic modalities to meet the unique needs of each individual patient [25]. It has been shown that multimodal therapies can significantly enhance the quality of life of survivors of TBI [26]. This evidence highlights the effectiveness of a personalized approach that takes into account cultural and gender differences, leading to substantial improvement in outcomes for patients.

This case report contributes to the growing body of evidence supporting the use of holistic and patient-centered methods in TBI rehabilitation [26]. It underscores the importance of a comprehensive psychotherapeutic approach in managing TBI. VR's case adds to existing literature by demonstrating the efficacy that comes with integrating CR into REBT and CFT. Because of the preference of surgical and pharmacological interventions in TBI, psychotherapeutic management remains underrepresented, particularly in India [28–30]³.

The therapeutic approach has played a crucial role in VR's progress, aligning with research indicating that a collaborative relationship improves outcomes for TBI patients³. VR showed significant improvements in daily functioning, emotional regulation, and cognitive abilities, supporting the case for the effectiveness of a holistic and personalized therapeutic approach [23]. VR's attitude towards this comprehensive approach was assessed through clinical interviews and SUD. She reported feeling more able to engage and understanding compared to previous treatments, noting that addressing both the cognitive and emotional aspects of TBI simultaneously felt more reasonable. VR expressed particular appreciation for the self-compassion elements of CFT.

This case highlights the necessity for comprehensive neurorehabilitation programs that incorporate psychological therapies, alongside cognitive rehabilitation. Future efforts should focus on training mental health professionals in neurorehabilitation and designing multimodal therapeutic intervention protocols that are tailored to individual needs.

In conclusion, the integration of REBT, CFT, and CR in the treatment of TBI demonstrates the potential for improving recovery and quality of life. This holistic approach

² Available from: <https://www.tbimedslp.com/blog/traumatic-brain-injury-rehabilitation>

³ Available from: <https://newsroom.uw.edu/news-releases/collaborative-care-model-reduces-tbi-pain-study-shows>

addresses the intricate interplay of cognitive, emotional, and behavioral challenges, emphasizing the need for personalized care in TBI rehabilitation.

Future efforts should include a reassessment of the NIMHANS Neuropsychological Battery of tests used to assess patient improvements in order to produce parametric data that allow for assessing the dynamics of a patient's condition, confirming the advantages of this comprehensive approach in the treatment of patient objectively.

When juxtaposed with our initial aim, this case study has allowed us to achieve significant progress while also highlighting areas for future research. Our efforts have contributed to addressing the gap in the literature on the comprehensive psychotherapeutic management of TBI in the Indian context, though more research is needed. This case has successfully demonstrated the potential benefits of a holistic, patient-centered approach that takes into account cognitive limitations, cultural factors, and individual needs. The integration of REBT, CFT, and CR shows promising results in efforts to improve emotional regulation, cognitive functioning, and quality of life for patients with TBI, in line with our aim to explore the synergistic effects of combined therapies. This case adds to the growing body of evidence that supports integrative approaches in neurorehabilitation, emphasizing the importance of combining psychological interventions with cognitive rehabilitation. It effectively highlights the value of flexible, tailored interventions that address both the cognitive and emotional aspects of TBI recovery, while providing valuable insights into the practical application of an integrated approach and laying the groundwork for future studies. This case study also underscores the need for large-scale, quantitative research to more definitively demonstrate the efficacy of this approach in TBI rehabilitation.

Limitations

As the authors of this case report, we acknowledge several limitations in our work. Our single-case design, while providing valuable insights, limits any generalization to the broader TBI population. We relied primarily on SUD for outcome measurement, which, although clinically useful, lacks the objectivity of standardized measures. Our report would have benefited from more comprehensive pre- and post-intervention neuropsychological assessments to objectively quantify cognitive improvement. We also recognize the absence of long-term follow-up data, which could have demonstrated the durability of the observed

improvements. Despite these limitations, we believe our case report offers valuable insights into an integrated approach for TBI rehabilitation, laying the groundwork for future, more rigorous studies in this area.

CONCLUSION

This case report demonstrates a successful integration of REBT, CFT, and TBI. The holistic, personalized approach effectively addressed the multifaceted psychological and cognitive challenges faced by the patient, promoting recovery and enhancing her quality of life. These findings underscore the importance of incorporating diverse therapeutic modalities in TBI management and highlight the need for further research and adoption of such approaches in clinical practice.

Informed consent: Informed consent was secured in written and signed form on August 8, 2024.

Article history

Submitted: 31.05.2024

Accepted: 28.10.2024

Published Online: 10.12.2024

Authors' contribution: Shweta Mahajan contributed to conceptualization of the work, the therapy sessions and formulation of the case. She was primarily responsible for the investigation and methodology, as well as the writing of the original draft of the manuscript and participated in its review and editing. Anuja Jain conducted and analyzed the psychological assessments used in this work. She was responsible for data curation and formal analysis of the assessment results, contributing to the investigation process. Shamli Themse — conceptualization and supervision. She was responsible for project administration, including securing informed consent from participants and provided resources. Themse also contributed to the validation of the study's findings and methodologies. Shreshta Chattopadhyay made a significant contribution to the manuscript through supervision, visualization, extensive editing, and conceptualization. She was primarily involved in the review & editing phases, helping to refine and improve the final version of the paper. All the authors approved the final version of the article.

Funding: The research was carried out without additional funding.

Conflict of interest: The authors declare no conflicts of interest.

For citation:

Mahajan SN, Jain A, Chattopadhyay S, Themse S. Integrating rational emotive behavior therapy, compassion-focused therapy with cognitive retraining in traumatic brain injury: a clinical case. *Consortium Psychiatricum*. 2024;5(4):CP15546. doi: 10.17816/CP15546

Information about the authors

***Shweta Nitin Mahajan**, MPhil, Clinical Psychology Trainee, Department of Clinical Psychology, Rashtriya Raksha University; ORCID: <https://orcid.org/0000-0002-7180-6568>
E-mail: mnshwetaa1011@gmail.com

Anuja Jain, MPhil, Clinical Psychology Trainee, Department of Clinical Psychology, Rashtriya Raksha University

Shreshtha Chattopadhyay, Assistant Professor, Clinical Psychologist, Department of Clinical Psychology, Rashtriya Raksha University
Shamli Themse, Assistant Professor, Clinical Psychologist, Department of Clinical Psychology, Rashtriya Raksha University

*corresponding author

References

1. Mao G. Traumatic Brain Injury (TBI) [Internet]. MSD Manual Professional Edition; 2023 Feb [cited 2024 Aug 12]. Available from: <https://www.msmanuals.com/professional/injuries-poisoning/traumatic-brain-injury-tbi/traumatic-brain-injury-tbi>
2. Maas AIR, Menon DK, Manley GT, et al. Traumatic brain injury: progress and challenges in prevention, clinical care, and research. *Lancet Neurol*. 2022;21(11):1004–1060. doi: 10.1016/s1474-4422(22)00309-x
3. Dewan MC, Rattani A, Gupta S, et al. Estimating the global incidence of traumatic brain injury. *J Neurosurg*. 2021;130(4):1080–1097. doi: 10.3171/2017.10.JNS17352
4. Gururaj G, Kolluri SVR, Chandramouli BA, et al. Traumatic brain injury [Internet]. Bangalore: National Institute of Mental Health and Neuro Sciences; 2021 [cited 2024 Aug 12]. Available from: <https://nimhans.ac.in/wp-content/uploads/2021/02/Traumatic-Brain-Injury-Report.pdf>
5. Ashworth F, Clark A, Jones L, et al. An exploration of compassion focused therapy following acquired brain injury. *Psychol Psychother*. 2015;88(2):143–162. doi: 10.1111/papt.12037
6. Ashworth F, Gracey F, Gilbert P. Compassion Focused therapy after Traumatic Brain Injury: Theoretical foundations and a case illustration. *Brain Impairment*. 2011;12(2):128–139. doi: 10.1375/brim.12.2.128
7. Al-Roubaiy NS. One pathway to cognitive behaviour therapy integration: introducing assimilative integrative rational emotive behaviour therapy. *The Cognitive Behaviour Therapist*. 2020(13):e7. doi: 10.1017/s1754470x20000069
8. Agrawal A, Munivenkatappa A, Shukla DP, et al. Traumatic brain injury related research in India: An overview of published literature. *Int J Crit Illn Inj Sci*. 2016;6(2):65–69. doi: 10.4103/2229-5151.183025
9. Dash HH, Chavali S. Management of traumatic brain injury patients. *Korean J Anesthesiol*. 2018;71(1):12–21. doi: 10.4097/kjae.2018.71.1.12
10. Mahajan M, Hegde S, Sinha S. Lost Self to Present Self: A Case Report of Narrative Therapy for a Woman with Acquired Brain Injury. *Consort Psychiatr*. 2024;5(1):34–43. doi: 10.17816/cp15477
11. Hofmann SG, editor. *The Wiley Handbook of Cognitive Behavioral Therapy*. [S. l.]: Wiley-Blackwell, 2013.
12. Aita SL, Schuler KR, Isaak SL, et al. Posttraumatic Stress Disorder complicated by Traumatic Brain Injury: A Narrative review. *SN Comprehensive Clinical Medicine*. 2023;5(1). doi: 10.1007/s42399-023-01431-1
13. Rowland S M, Lam, CS, Leahy B. Use of the beck depression inventory-II (BDI-II) with persons with traumatic brain injury: Analysis of factorial structure. *Brain Inj*. 2005;19(2):77–83. doi: 10.1080/02699050410001719988
14. Chong MC, Sharp MK, Smith SM, et al. Strong recommendations from low certainty evidence: a cross-sectional analysis of a suite of national guidelines. *BMC Med Res Methodol*. 2023;23(1):68. doi: 10.1186/s12874-023-01895-8
15. Murray H. F06.32 – Mood Disorder Due to Known Physiological Condition With Major Depressive-like Episode [Internet]. *Carepatron*; 2014 [cited 2024 Aug 12]. Available from: <https://www.carepatron.com/icd/f06-32>
16. Wolpe J. *The practice of behavior therapy*. New York: Pergamon Press; 1969.
17. Randall, D, Thomas M, Whiting D, et al. Depression Anxiety Stress Scales (DASS-21): Factor structure in Traumatic Brain Injury Rehabilitation. *J Head Trauma Rehabil*. 2017;32(2):134–144. doi: 10.1097/htr.0000000000000250
18. Deng X, Mu T, Wang Y, et al. The application of human figure drawing as a supplementary tool for depression screening. *Front Psychol*. 2022;13:865206. doi: 10.3389/fpsyg.2022.865206
19. Afsar M, Shukla D, Bhaskarapillai B, et al. Cognitive Retraining in Traumatic Brain Injury: Experience from Tertiary Care Center in Southern India. *J Neurosci Rural Pract*. 2021;12(2):295–301. doi: 10.1055/s-0041-1722817
20. Pershad D, Verma SK. *Handbook of P G I Battery of Brain Dysfunction (pgi-BbD)*. [S. l.]: National Psychological Corporation; 1993.
21. Min JH, Shin Y. Treatment and Rehabilitation for Traumatic Brain Injury: current update. *Brain Neurorehabil*. 2022;15(2):e14. doi: 10.12786/bn.2022.15.e14
22. Blaya MO, Raval AP, Bramlett HM. Traumatic brain injury in women across lifespan. *Neurobiol Dis*. 2022;164:105613. doi: 10.1016/j.nbd.2022.105613
23. Riqueme SC, Prigatano GP. From meaning to symptom reduction: contemporary approaches to psychotherapy after traumatic brain injury. *Revista Chilena de Neuropsicología*. 2018;13(2):22–29.
24. Yeates KO, Bigler ED, Abildskov T, et al. Social Competence in Pediatric Traumatic Brain Injury: From Brain to Behavior. *Clin Psychol Sci*. 2013;2(1):97–107. doi: 10.1177/2167702613499734
25. Doucet BM. Neurorehabilitation: are we doing all that we can? *Am J Occup Ther*. 2012;66(4):488–493. doi: 10.5014/ajot.212.002790
26. Howe EI, Zeldovich M, Andelic N, et al. Rehabilitation and outcomes after complicated vs uncomplicated mild TBI: results from the CENTER-TBI study. *BMC Health Serv Res*. 2022;22(1):1536. doi: 10.1186/s12913-022-08908-0
27. Donnelly K, Nelson J, Zeller S, et al. LoveYourBrain Retreats Improve quality of Life After Brain Injury [Internet]. *BrainLine*; 2023 January 13 [cited 2024 Aug 12]. Available from:

<https://www.brainline.org/research/loveyourbrain-retreats-improve-quality-life-after-brain-injury>

28. Lexell J, Larsson Lund M, Möller M, et al. Rehabilitering för vuxna med traumatisk hjärnskada: En systematisk översikt och utvärdering av medicinska, ekonomiska, sociala och etiska aspekter [Internet]. Statens beredning för medicinsk och social utvärdering; 2019 [cited 2024 Aug 12]. Available from: <https://www.ncbi.nlm.nih.gov/books/NBK566652>
 29. Block CK, West SE. Psychotherapeutic treatment of survivors of traumatic brain injury: review of the literature and special considerations. *Brain Inj.* 2013;27(7-8):775-788. doi: 10.3109/02699052.2013.775487
 30. Gómez-de-Regil L, Estrella-Castillo DF, Vega-Cauich J. Psychological intervention in traumatic brain injury patients. *Behav Neurol.* 2019;2019: 6937832. doi: 10.1155/2019/6937832
-